ILA - Internal Ligament Augmentation with Mini Expert in the Treatment of Thumb CMC Joint Osteoarthritis

Márcio Aita , MD

ABC Hand Center
Centro Cirúrgico Ambulatorial

Literature Review

CMC joint osteoarthritis at the base of the thumb may have inflammatory, traumatic or idiopathic origin, the latter being the most prevalent in postmenopausal women.

In addition to being a frequent entity, is the main cause of functional disability, being of great importance in the impact on the performance of daily and work activities. Initially, the joint becomes painful and, in the final stage, joint stiffness and deformity of the adducted thumb appear.

Conservative treatment is the first line of treatment, which involves rest, immobilization, non-steroidal anti-inflammatory drugs, physical therapy and intra articular injection of corticosteroids.

In cases of pain and/or functional disability that persist after conservative treatment and that significantly interfere with daily activities, surgery is the indicated treatment. Due to the high prevalence and the important psychosocial impact caused by the disease, there are numerous surgical techniques recommended in the treatment of CMC joint arthritis, whose common goal is always to improve pain, deformity, mobility and thumb pinch strength.

Among the various surgical treatment modalities published in the literature, there is the direct approach and the minimally invasive technique, which present some differences between them.

When should I use minimally invasive technique?

The conventional approach has an immobilization time of 6 weeks, while the minimally invasive technique has a maximum time of 10 days. The recovery time and return to work of the patient submitted to a direct approach is also significantly longer than that submitted to a less invasive technique, with the duration lasting almost 6 months, and in the last, it may be from 15 days to 2 months. Finally, conventional surgery lasts 1 hour longer than the minimally invasive technique.

Arthroscopic trapezectomy combined with suspensoplasty with ILA - Internal Ligament Augmentation using GMReis Ø3.5 x 8.5 mm Fastlock Knotless Tape Loaded Anchor combined with GMReis Mini Expert botton, to provide a minimally invasive technique is an innovative and effective alternative treatment, avoid pain, iatrogenic metacarpal fracture and stiffness in CMC joint.

Fig.: 3d model with combined use of GMReis Mini Expert and GMReis Fastlock Knotless Anchor for suspensoplaty in rhizarthrosis treatment.

Tips for hemitrapeziectomy assisted by arthroscopy and suspensoplasty in CMC joint with flexible fixation

Arthroscopy provides a clearer view of the degree of degeneration that affects the joint, even if compared to magnetic resonance imaging. In addition, it is also a precise procedure in the treatment, which promotes the removal only of degenerated tissues, preserving the structures not affected by the disease. The minimally invasive technique described is advantageous because the tissues to be healed are smaller. During resection of the distal portion of the trapezius, the most difficult portion to access is the osteophyte between the bases of the first and second pasterns, which will allow the reduction and correction of the positioning of the thumb. This approach also does not dissect the dorsal capsule, which allows proprioception and stabilization of the CMC joint. In addition, tendons are not used to perform suspensoplasty, due to the use of the flexible fixation (only one GMReis Mini Expert botton associated

with GMReis Ø3.5 x 8.5 mm Fastlock Anchor and tape), promoting the maintenance of thumb function with advantageous:

- **Bone tunnel about 1.6 mm into second metacarpal bone (avoid iatrogenic fracture in metacarpal);**
- **Without implants or knot adjacent base of the first thumb (avoid pain around base the thumb);**
- **The best control to maintenance gothic arc between first and second metacarpal articular faces congruence (avoid stiffness and impact around first/second metacarpal) and,**
- **The use of GMReis Stitch Tape instead of convencional sutures (wires) provides high resistence system to maintain suspensoplasty technique.**



Fig.: GMReis Mini Expert for flexible fixation highlighted the rectangular botton used in related technique.



Fig.: GMReis Ø3.5 x 8.5 mm Fastlock SA Knotless Tape Loaded Anchor with open eyelet.

There is just propor level of evidence but the present author prefers and recommend to use ILA with GMReis Fastlock anchor when after CMC Arthroscopy, fisrt metacarpal to mantain unstable:

- **Dorsal dislocation of first metacarpal and shortening first finger.**

This is typically the case for CMC arthritis and also when axial and longitudinal instability of the CMC joint is evident:

Figs.: Minimally invasive x Conventional approaches to treat CMC joint arthritis: The minimally invasive technique described is advantageous because the tissues to be healed are smaller. This approach also does not dissect the dorsal capsule, which allows proprioception and stabilization of the CMC joint.

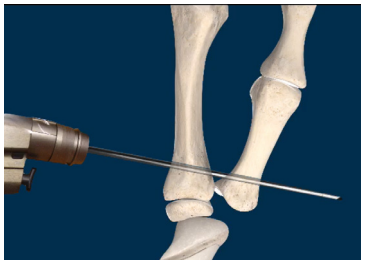

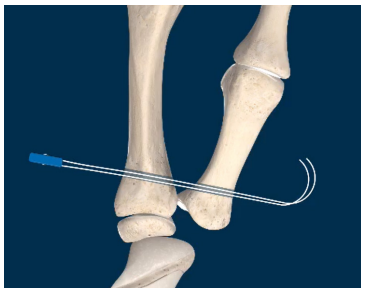

Figs.: To perform trapeziectomy assisted by arthroscopy To pass: guide wire (1.6 mm), and mini expert (GMReis Mini Expert rectangular botton combined with GMReis Stitch Suture Tape to provide ILA - Internal Ligament Augmentation) since base second to first metacarpal direction in neutral position and transverse direction. After, pass drill (unicortical, lateral to medial direction, in base the first metacarpal and fix the tape with GMReis Ø3.5 x 8.5 mm Fastlock Knotless Anchor.

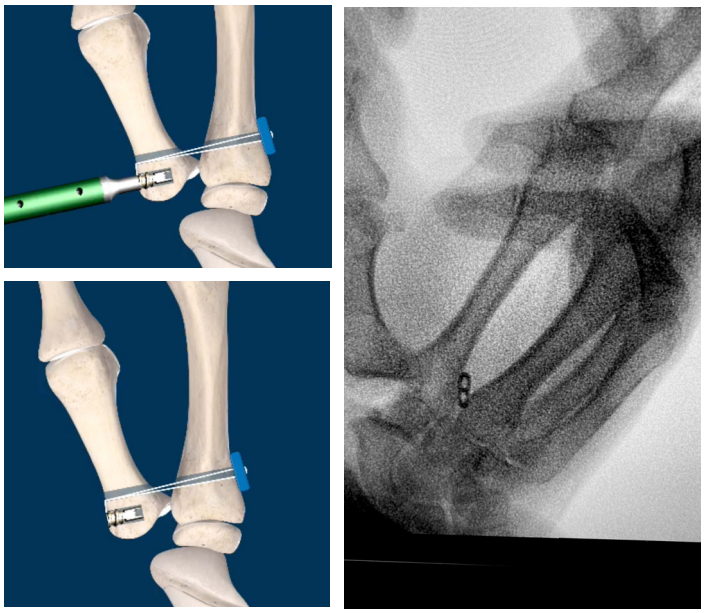

Figs.: Post op Radiographic aspects: Arthroscopic thrapezectomy combined with ILA suspensoplasty with GMReis Mini Expert botton and Fastlock anchor. Check maintenance first / second metacarpal articular faces congruence and gothic arc, without knot or implant around the base of the first metacarpal and thin bone tunnel into metacarpals.



MINI EXPERT – IMPLANT

CODE	DESCRIPTION
311-2000	Mini Expert – Flexible Fixation



FASTLOCK IMPLANT

CODE	DESCRIPTION
320-35085-SA	Fastlock Knotless Tape Loaded PEEK Anchor Ø3.5 x 8.5 mm Open eyelet

Surgical Technique

The choice of treatment depends on the stage of arthritis classified by Eaton and Littleras: initial (stages I and II), intermediate (III) and severe (IV). The surgery can be performed in cases of established arthritis. CMC arthrodesis can be performed in younger and more active patients, with arthritis in stages II and III. Isolated thrapeziectomy is performed in elderly patients, who do not require strength or function, with arthritis in stages II and IV. On the other hand, Arthroscopic total ou hemitrapeziectomy combined with suspensoplasty with only one Mini Expert botton associated with Fastlock ILA - Internal Ligament Augmtation is a feasible surgical option for late CMC arthritis and this effect is maintained over time, proving to be a safe and reliable method, through satisfactory clinical results.

Fig.: GMReis Mini Expert combined with GMReis Fastlock Knotless Anchor for zero profile suspensoplaty.

References:

1. Barron OA, Glickel SZ, Eaton RG. Basal joint arthritis of the thumb. J Am Acad Orthop Surg. 2000;8(5):314-23;
2. Badia A. Arthroscopy of the trapeziometacarpal and metacarpophalangeal joints. J Hand Surg Am. 2007;32(5):707–24;
3. Menon J. Arthroscopic management of trapeziometacarpal joint arthritis of the thumb. Arthroscopy. 1996;12(5):581–7;
4. Weiss AC, Goodman AD. Thumb Basal Joint Arthritis. J Am Acad Orthop Surg. 2018;26(16):562-577;
5. Cox CA, Zlotolow DA, Yao J. Suture button suspensionplasty after arthroscopic hemitrapeziectomy for treatment of thumb carpometacarpal arthritis. Arthroscopy. 2010;26(10):1395-1403;
6. Landes G, Gaspar MP, Goljan P, Jacoby SM, Bachoura A, Culp RW. Arthroscopic Trapeziectomy With Suture Button Suspensionplasty: A Retrospective Review of 153 Cases. Hand (N Y). 2016;11(2):232-23;
7. Özçelik İB, Uğurlar M, Sarı A. Arthroscopic Hemitrapeziectomy and Suture Button Suspensionplasty in the Treatment of First Carpometacarpal Joint Eaton-Littler Stage 2-3 Arthrosis. J Wrist Surg. 2019;8(2):132-138.
8. Slutsky DJ. The use of a dorsal-distal portal in trapeziometacarpal arthroscopy. Arthroscopy. 2007;23(11):1244.e1-1244.e12444.

GMREIS
Qualidade para Vida
Calidad para Vida Quality for Life الجودة للحياة