# Arthroereisis For Flat Foot

Cristian Ortiz, MD
Clinica U de Los Andes

## Historic perspective

The word arthroereisis comes from "arthros" (joint) and "ereisis" (support) , which finally means support for the joint.

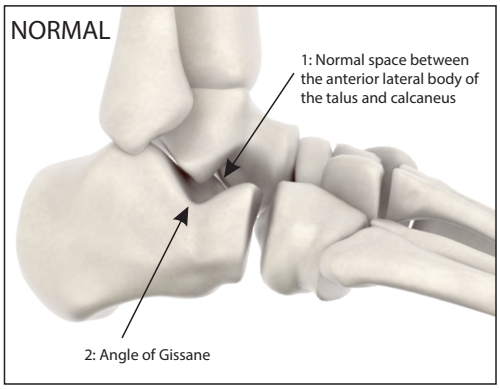


The first description of a such a technique was published in 1946 by Chambers using a bone block in flexible flat feet in adolescents.

It became more popular after Grice described in 1952 his technique of an extra-articular arthrodesis of the subtalar joint for the correction of paralytic flat feet in children.

More recently, in 1970, it was Lelievre who describe the bone block without arthrodesis in the correction of flat feet.

A few year later (1977) Subotnick described the silicone implant for the sinus tarsi.

Several implants were described for the sinus tarsi being " the cup of Viladot " (Kalix) being by far the most popular one. He reported 99% of successful results in 234 children.

The technique for flexible flat feet in children and adolescents becames popular in Europe, from where it spread out to the rest of the world, but interestingly enough it did not became popular in the United States until the last 20 years.

Myerson reported good results in 23 children but mentioned the need of removal in about 10% of cases without loss of correction in follow up.

Most of us saw that even though a good simptoms was achieved in several patients, some did not obtained good anatomical correction and several showed lost of the implant position.

*Figs: Shows loss of position of an arthoereisis of the sinus tarsi. The latest advances in implant development more towards a tarsal canal implant that seems to produce better correction with less loss of positions compared with implants in the sinus tarsi.*

## How does it work?

Although there is no consensus about how or why it works, it makes sense than since in blocks eversion and produces at the same time some sort of lengthening of the lateral column. By this mechanism the implant produces correction in three planes, improving the arch, hindfoot valgus and abduction.

In some children´s hospitals a variation of the technique

became very popular because it was cheap and showed good results ("calcaneo stop"). In this technique a simple screw was inserted in the calcaneus leaving a prominent head facing the lateral process of the talus, so it could block eversion. A similar technique has been describe using the screw in the lateral process of the talus instead of the calcaneus.

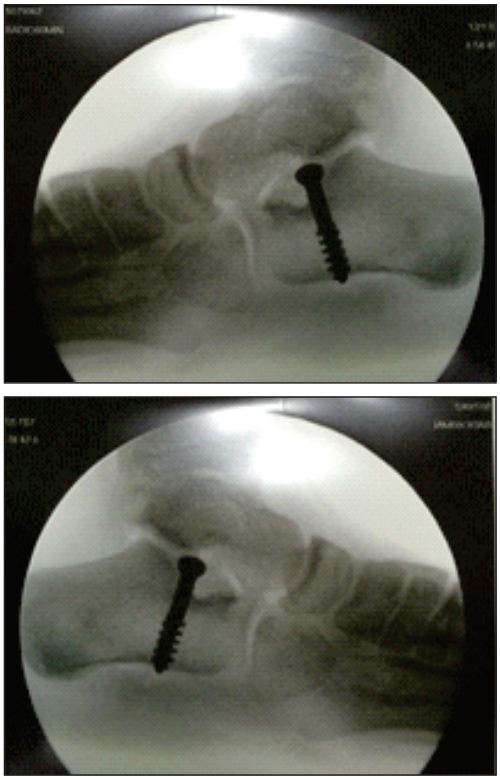

*Fig: "Calcaneo stop technique".*

## Indications

Classical surgical indication for painful flat feet that did not respond to conservative treatment includes

1- Soft tissues: Tendon transfers, medial ligaments reconstruction, achilles tendon lengthening, etc;

2- Osteotomies: calcaneal , lateral column lengthening, cotton, etc; and

3- Arthrodesis triple and double.

Arthrodesis has been classically restricted for patient with closed growth physis, and the other techniques have been used in different combinations depending on patients conditions and surgeons preferences.

For many years the major indication for arthroereisis was flexible flat feet in children. But several authors noted good results with low morbidity and started to use it as complementary technique in adult. So, some reports showed arthroereisis in combination with medial soft tissue reconstruction, medializing calcaneal osteotomy, tendon tranfers, etc.

Some authors like Fernandez de Retana recommends arthoereisis in adult with flexible flat feet.

Since morbidity related to the implant has been shown to be mild, indication has been extended for more patient without a clear limit in age.

## Surgical technique:

Patient is in prone position. Local anesthesia and sedation is enough for most patients.

A 2 centimeters transverse incision is made in the sinus tarsi. Correct orientation of this canal is proved with a Ø1.8 Rounded KWire and its position check with X-rays.

A Cannulated Probe can be used to dilate the tarsal canal.

Then size of the implant is tested so it is able to be positioned in the tarsal canal with its lateral part at the level of the lateral neck of the talus. Then the implant is screwed in double checking the final position with X-rays.



*Fig: Surgical technique showing small incision during implant insertion.*

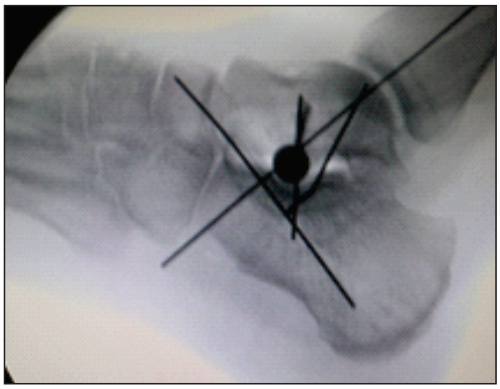

*Fig: shows intraop X-rays insertion of ARTROM GMREIS arthroereisis screw.*

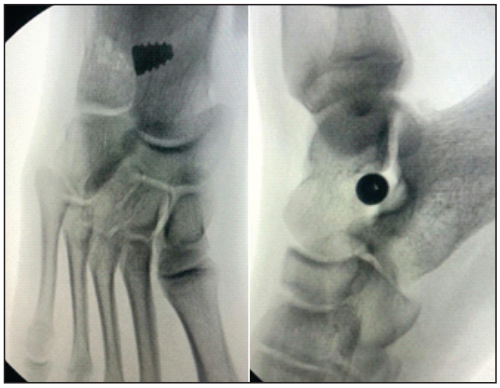

*Fig: shows intraop X-ray of ARTROM GMREIS arthroereisis screw in tarsal canal.*
*Images cordially provided by Mohamed Albaqali, MD.*

## Results

There is no level one evidence to prove how good this technique is, but general experience among authors show that indication is growing.

It has low morbidity with mild pain that typically forces the patient to walk on the lateral side of the foot for a few days or weeks. We allow them walk freely as tolerated and advice them that they may go back to sports between 3 to 6 months and that they might need implant removal if pain persist at the insertion area.

It has been interesting to see that patients do not seem to loose correction in case of removal.

*Figs: preop pictures showing valgus, flat arch and abduction.*

*Fig: post op pictures of the same patient showing correction.*

GMREIS
Qualidade para Vida
Calidad para Vida Quality for Life الجودة للحياة


*Fig : X-ray with tarsal canal implant in good position.*

## Summary

Arthroereisis has shown excellent results with minimal morbidity, explaining why so many surgeons are using it more and more with very happy patients.

Cristian Ortiz, MD

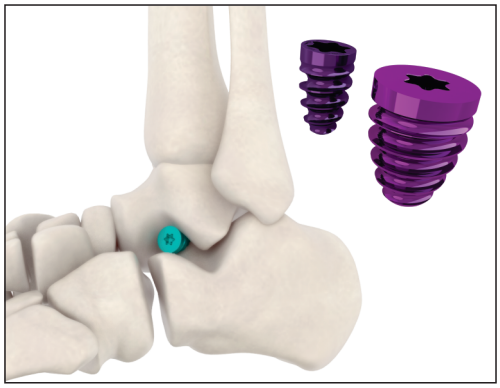

### IMPLANTS

| Code | Description | Qty | Colour |
|---|---|---|---|
| 241-70-12 | Artrom – Arthroereisis Screw Ø7.0 mm | 02 | |
| 241-90-14 | Artrom – Arthroereisis Screw Ø9.0 mm | 02 | |
| 241-100-14 | Artrom – Arthroereisis Screw Ø10.0 mm | 02 | |
| 241-110-16 | Artrom – Arthroereisis Screw Ø11.0 mm | 02 | |
| 241-120-16 | Artrom – Arthroereisis Screw Ø12.0 mm | 02 | |




### INSTRUMENTALS

| Code | Description | Qty | Colour |
|---|---|---|---|
| 241-32 | Ø1.8 x 310 mm Rounded K Wire | 10 | |
| 241-200 | Artrom Cannulated Driver | 01 | |
| 241-300 | Artrom Cannulated Probe | 01 | |
| 241-7012-T | Artrom Cannulated Trial Ø7.0 mm | 01 | |
| 241-9014-T | Artrom Cannulated Trial Ø9.0 mm | 01 | |
| 241-10014-T | Artrom Cannulated Trial Ø10.0 mm | 01 | |
| 241-11016-T | Artrom Cannulated Trial Ø11.0 mm | 01 | |
| 241-12016-T | Artrom Cannulated Trial Ø12.0 mm | 01 | |
| 241-1000 | Artrom Implants and Instruments Tray | 01 | |

### References:

Chambers EF. An operation for the correction of flexible flat feet of adolescents. WestJ Surg Obstet Gynecol 1946;54:603–4.

Grice DS. An extra-articular arthrodesis of the subastragalar joint for correction of paralytic flat feet in Children. J Bone Joint Surg Am 1952;34:927–40

Lelievre J. The valgus foot: current concepts and correction. Clin Orthop 1970;70:43–55.

Zaret DI, Myerson MS. Arthroereisis of the subtalar joint. Foot Ankle Clin North Am 2003;8:605–17

Needleman RL. Current topic review: subtalar arthroereisis for correction of flexible flatfoot. Foot Ankle Int 2005;26:336–46

Subotnick S. The subtalar joint lateral extra-articular arthroereisis: a follow-up report.J Am Podiatry Assoc 1977;32:27–33.

Arangio GA, Reinert KL, Salathe EP. A biomechanical model of the effect of subtalar arthroereisis on the adult flexible flat foot. Clin Biomech 2004;19:847–52.

Is There a Role for Subtalar Arthroereisis in the Management of Adult Acquired Flatfoot? Pablo Fernández de Retana, MDa,, Fernando Álvarez, MDGustavo Bacca, FAC 2012

The Calcaneo-Stop Procedure F.G. Usuelli, MD*, U. Alfieri Montrasio, MD. FAC 2012

Magnan B, Baldrighi C, Papadia D. Flatfeet: comparison of surgical techniques.Result of study group into retrograde endorthesis with calcaneus-stop. Ital J Pediatr Orthop 1997;13:28–33.

Schon LC. Subtalar arthroereisis: a new exploration of an old concept. Foot Ankle Clin North Am 2007;12:329–39,

GMReis
Qualidade para Vida
Calidad para Vida Quality for Life الجودة للحياة