Fastbridge - Double Row Technique in Achilles Insertional Tendinopathy

Cristian Ortiz, MD
Clinica U de Los Andes

Introduction:

Achilles tendinopathy is one of the most common overuse injuries in athletes. It may be non insertional (50%) or insertional (20%). The other 30% is combined insertional and no insertional although is pathogenesis is not fully understood there seems to be consensus that it is related to overuse and also to anatomical factor like what has been called the Haglund´s deformity. This is a prominent posterosuperior calcaneal tuberosity that may produce impingement at the distal insertion of the achilles tendon. It may be related to bursitis and to a variable range of distal achilles tendinopathy.

Diagnosis:

The patient typically complains of dorsal heel pain that gets worse with sprint sports. It is worse when movement begins and then it gets better when the patient warms up. Then it gets worse again as the physical activity increases. Most of the time medical consultation is delayed more than 3 months .

A painful bump may be observed on physical examination.

Fig: painful bump on physical examination.

Fig: X-rays may show variable degrees of calcification at the insertional area of the achilles tendon.

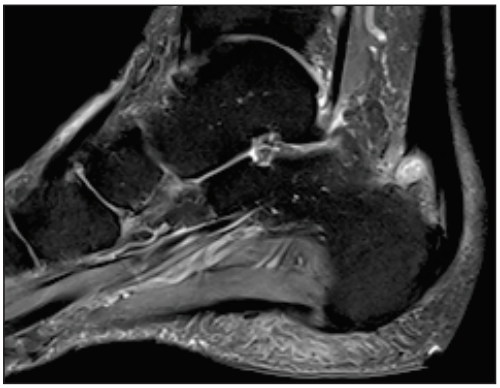

Fig: MRI shows degenerative changes at the insertion of the achilles tendon as well as bone edema at the impingement area.

Although we tend to think that pain is strictly related to the anatomical changes found in X-rays, US and MRI this is not necessarily the truth. Some extremely symptomatic patients may have subtle changes in any of these tests. On the other side, some severe changes may be seen in completely asymptomatic patients.

This disease is another good example in which symptoms and clinical findings are the ones guiding our decisions.

Conservative treatment:

There is good level of evidence to recommend different types of conservative treatment. These include modifying physical activity, physical therapy with eccentric exercises, shock wave therapy, etc.

Cortisone injections are not recommended because of the risk of tendon ruptures. Some other liquid infiltrations that have been used in noninsertional achilles tendinopathy are not recommended for its insertional variant. If conservative treatment fails to show improvement over 3 to 6 months, then a surgical treatment is recommended.

Surgical treatment:

Different surgical options have been recommended. For the less severe cases in which there is just minor damage to the achilles tendon an arthroscopic Haglund resection has been described. This technique seems to work only in cases without evident tendon damage. In 2006 Wagner showed that tendinopathy is typically underestimated in preoperative images . So they recommended to always a reattachment of the distal insertion of the tendon.

Although results of reattachment with classical anchor were promising , the rehabilitation time was classically very long.

Fig: Show classical intraoperative findings ins distal achillles insertional tendinopathy in which at least the lateral 50% of the tendon has degenerative changes.

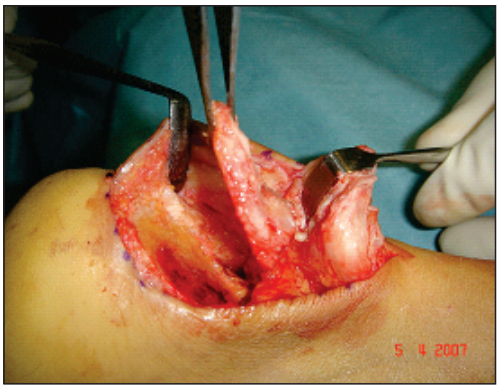

Fig: Haglund´s resection with complete detachment of the achilles insertion.

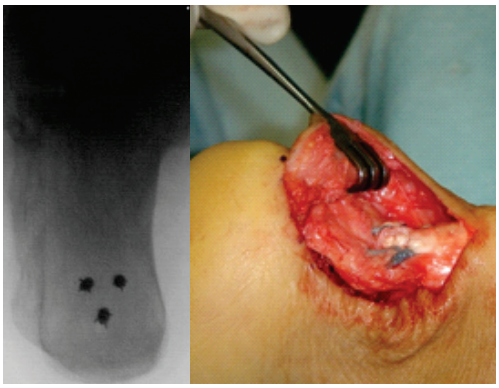

Figs: Show the old fashion technique with anchors reattachment.

With the recently available technique of Haglund resection, debridment of the distal pathologic tendon but reattachment with tape loaded anchors in a "W" figure a much more stable construct allowed surgeons to move on with a more aggressive rehabilitation protocol.

Its better stability has been biomechanically and clinically tested. Its advantages are related to several factors:

1 - Distal insertion of the achilles tendon is opened like a book removing the central part which is typically the most diseased tendon. This preserves the lateral attachment so length is not lost and also keeps some mechanical strength;

2 - The tape grabs more surface of the tendon against a well vascularized area after resection of the Haglund´s deformity; and

3 - Two rows of knotless anchors allow a bigger surface of the healthy tendon against the bone and with more stable construct.

The anchors are knotless so there is no irritation of sutures compared with the old fashion anchors technique.

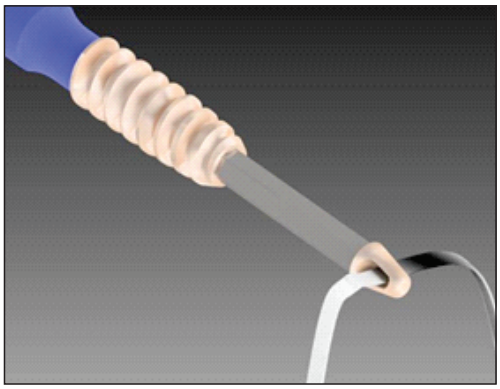

Figs: Showing GMREIS FASTLOCK knotless tape loaded anchor.

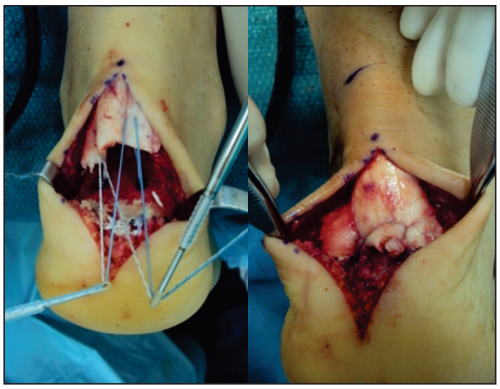

Figs: Show reattachment with a Fastbridge double row of knotless anchors.

CLINICAL CASE:

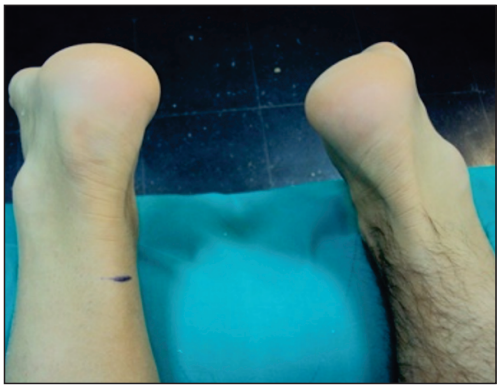

Fig: 35y patient with distal achilles insertional tendinopathy.

Fig: Intraop images showing severely damaged central achilles tendon.

Post op rehabilitation:

We typically keep the patient weight bearing as tolerated in a removable boot for 2 to 3 weeks. Then, we remove the sutures and send them to physical therapy to progressively go back to daily activities and sports as tolerated.

Most patients are able to get rid of the boot as early as 3 to 4 weeks and begin with progressive load. Some athletes are able to go back to sports between 3 to 6 months.

It must be mentioned that there are some cases in which there is such a complete damage of the whole tendon that it must be replaced by an allograft. In some other the muscle (triceps surai) may be atrophic and useless to repair. Then a FHL tendon transfer to replace the diseased tendon an muscle may be indicated.

Fig: Show Fastbridge "W" configuration of sutures with GMReis Fastlock knotless tape loaded anchors.

Summary:

For the disabling achilles insertion tendinopathy the Fastbridge technique provides a significant improvement in recovery time. It allows surgeons to leave the patient without protection and start rehabilitation as soon as tolerated.

Most of the time this quicker recovery time makes the difference between persisting on conservative treatment for a long period of time or performing a surgery with low associated morbidity and excellent results.

Cristian Ortiz, MD

Fastlock - Knotless Tape Loaded Anchor:

Ø4,75 mm

IMPLANTS

Code	Description
320-475191-PE5	Fastlock Knotless Tape Loaded PEEK Anchor Ø4.75 x 15.0/19.1 mm

Ø4.75 mm FASTLOCK INSTRUMENTS

Code	Description
320-110	Fastlock Drill Guide
320-110-34	Ø3.4 x 110 mm Drill Bit
320-FL-475	Ø4.75 mm Fastlock Tap

References:

van Dijk CN, van Sterkenburg MN, Wiegerinck JI, Karlsson J, Maffulli N. Terminology for Achilles tendon related disorders. Knee Surg Sports Traumatol Arthrosc 2011;19:835-841. 7. Watson AD, Anderson RB, Davis WH.

"Current Concept Review: Noninsertional achilles tendinopathy", P Hecht. Foot Ankle Int Nov 2009

Systematic Review With Video Illustration Surgical Treatment of Chronic Retrocalcaneal Bursitis Johannes I. Wiegerinck, M.Sc., Aimee C. Kok, M.D., and C. Niek van Dijk, M.D., Ph.D Arthroscopy: The Journal of Arthroscopic and Related Surgery, Vol 28, No 2 (February), 2012: pp 283-293

Technique and results of Achiles Tendon Detachment and reconstruction for Insertional Achilles Tendinosis Emilio Wagner, John Gould, et la , Journal of Foot and Ankle International 2006